

# Effects of antiplatelet therapy on stroke risk by brain imaging features of intracerebral haemorrhage and cerebral small vessel diseases: subgroup analyses of the RESTART randomised, open-label trial



Rustam Al-Shahi Salman, David P Minks, Dipayan Mitra, Mark A Rodrigues, Priya Bhatnagar, Johann C du Plessis, Yogish Joshi, Martin S Dennis, Gordon D Murray, David E Newby, Peter A G Sandercock, Nikola Sprigg, Jacqueline Stephen, Cathie L M Sudlow, David J Werring, William N Whiteley, Joanna M Wardlaw, Philip M White, on behalf of the RESTART Collaboration\*



## Summary

**Background** Findings from the RESTART trial suggest that starting antiplatelet therapy might reduce the risk of recurrent symptomatic intracerebral haemorrhage compared with avoiding antiplatelet therapy. Brain imaging features of intracerebral haemorrhage and cerebral small vessel diseases (such as cerebral microbleeds) are associated with greater risks of recurrent intracerebral haemorrhage. We did subgroup analyses of the RESTART trial to explore whether these brain imaging features modify the effects of antiplatelet therapy.

**Methods** RESTART was a prospective, randomised, open-label, blinded-endpoint, parallel-group trial at 122 hospitals in the UK that assessed whether starting antiplatelet therapy might reduce the risk of recurrent symptomatic intracerebral haemorrhage compared with avoiding antiplatelet therapy. For this prespecified subgroup analysis, consultant neuroradiologists masked to treatment allocation reviewed brain CT or MRI scans performed before randomisation to confirm participant eligibility and rate features of the intracerebral haemorrhage and surrounding brain. We followed participants for primary (recurrent symptomatic intracerebral haemorrhage) and secondary (ischaemic stroke) outcomes for up to 5 years (reported elsewhere). For this report, we analysed eligible participants with intracerebral haemorrhage according to their treatment allocation in primary subgroup analyses of cerebral microbleeds on MRI and in exploratory subgroup analyses of other features on CT or MRI. The trial is registered with the ISRCTN registry, number ISRCTN71907627.

**Findings** Between May 22, 2013, and May 31, 2018, 537 participants were enrolled, of whom 525 (98%) had intracerebral haemorrhage: 507 (97%) were diagnosed on CT (252 assigned to start antiplatelet therapy and 255 assigned to avoid antiplatelet therapy, of whom one withdrew and was not analysed) and 254 (48%) underwent the required brain MRI protocol (122 in the start antiplatelet therapy group and 132 in the avoid antiplatelet therapy group). There were no clinically or statistically significant hazards of antiplatelet therapy on recurrent intracerebral haemorrhage in primary subgroup analyses of cerebral microbleed presence (2 or more) versus absence (0 or 1) (adjusted hazard ratio [HR] 0.30 [95% CI 0.08–1.13] vs 0.77 [0.13–4.61];  $p_{\text{interaction}}=0.41$ ), cerebral microbleed number 0–1 versus 2–4 versus 5 or more (HR 0.77 [0.13–4.62] vs 0.32 [0.03–3.66] vs 0.33 [0.07–1.60];  $p_{\text{interaction}}=0.75$ ), or cerebral microbleed strictly lobar versus other location (HR 0.52 [0.004–6.79] vs 0.37 [0.09–1.28];  $p_{\text{interaction}}=0.85$ ). There was no evidence of heterogeneity in the effects of antiplatelet therapy in any exploratory subgroup analyses (all  $p_{\text{interaction}}>0.05$ ).

**Interpretation** Our findings exclude all but a very modest harmful effect of antiplatelet therapy on recurrent intracerebral haemorrhage in the presence of cerebral microbleeds. Further randomised trials are needed to replicate these findings and investigate them with greater precision.

**Funding** British Heart Foundation.

**Copyright** © 2019 The Author(s). Published by Elsevier Ltd. This is an Open Access article under the CC BY 4.0 license.

## Introduction

Cerebral small vessel diseases cause, or contribute to, the majority of stroke due to intracerebral haemorrhage. Combinations of the many imaging biomarkers on brain CT and MRI can identify cerebral small vessel diseases such as cerebral amyloid angiopathy with reasonable accuracy.<sup>1–3</sup>

Some brain imaging features of intracerebral haemorrhage and cerebral small vessel diseases are associated with a higher risk of intracerebral haemorrhage recurrence in general, and in people taking antiplatelet therapy.<sup>4–8</sup> For example, the proportional increase in the risk of intracerebral haemorrhage recurrence is up to five-times higher after lobar versus non-lobar haemorrhage.<sup>8</sup>

*Lancet Neurol* 2019; 18: 643–52

Published Online

May 22, 2019

[http://dx.doi.org/10.1016/S1474-4422\(19\)30184-X](http://dx.doi.org/10.1016/S1474-4422(19)30184-X)

See [Comment](#) page 617

\*Members are listed in the appendix

Centre for Clinical Brain Sciences

(Prof R Al-Shahi Salman PhD,

M A Rodrigues FRCR,

Prof M S Dennis MD,

Prof P A G Sandercock DM,

Prof C L M Sudlow DPhil,

W N Whiteley PhD,

Prof J M Wardlaw FMedSci),

Usher Institute of Population

Health Sciences and

Informatics

(Prof R Al-Shahi Salman,

Prof G D Murray PhD,

J Stephen PhD,

Prof C L M Sudlow), Centre for

Cardiovascular Science

(Prof D E Newby DSc), and UK

Dementia Research Institute at

the University of Edinburgh

(Prof J M Wardlaw), University

of Edinburgh, Edinburgh, UK;

Department of

Neuroradiology,

Newcastle-upon-Tyne

Hospitals NHS Trust,

Newcastle-upon-Tyne, UK

(D P Minks FRCR, D Mitra MD,

P Bhatnagar FRCR,

Prof P M White MD); Institute of

Neuroscience and Newcastle

University Institute for Ageing,

Newcastle University,

Newcastle-upon-Tyne, UK

(D Mitra, Prof P M White);

Department of Clinical

Neurosciences, NHS Lothian,

Edinburgh, UK

(J C du Plessis FRCR);

Department of Radiology,

Addenbrooke's Hospital,

Cambridge, UK (Y Joshi FRCR);

Division of Clinical

Neurosciences, Faculty of

Medicine and Health Sciences,

University of Nottingham,

Nottingham, UK  
(Prof N Sprigg DM); and Stroke  
Research Group, Department of  
Brain Repair and  
Rehabilitation, University  
College London Queen Square  
Institute of Neurology,  
London, UK  
(Prof D J Werring PhD)

Correspondence to:  
Prof Rustam Al-Shahi Salman,  
Centre for Clinical Brain Sciences,  
University of Edinburgh,  
Edinburgh EH16 4SB, UK  
rustam.al-shahi@ed.ac.uk

See Online for appendix

## Research in context

### Evidence before this study

Brain imaging features of intracerebral haemorrhage (such as lobar location) and brain imaging biomarkers of cerebral small vessel diseases (such as microbleeds or superficial siderosis) are associated with a higher risk of intracerebral haemorrhage recurrence. Consequently, some physicians withhold antiplatelet therapy from people with these imaging features. However, it is unclear whether the effects of antiplatelet therapy vary by these brain imaging features. We searched MEDLINE Ovid (from 1948), Embase Ovid (from 1980), and bibliographies of relevant publications on Feb 28, 2019, combining search terms for cerebral small vessel diseases, intracerebral haemorrhage, randomised controlled trials, antiplatelet therapy, and brain imaging in humans (appendix). There were no language restrictions. The SPS3 randomised controlled trial showed no heterogeneity by brain MRI features in the effects of aspirin and clopidogrel versus aspirin alone in 1278 adults after subcortical ischaemic stroke. In the IST and CAST randomised controlled trials, there was no heterogeneity by visible infarction on brain CT in the effects of aspirin versus control in 31 072 adults after acute ischaemic stroke. However, no published randomised trials have reported the effects of antiplatelet therapy after intracerebral haemorrhage by brain imaging features.

### Added value of this study

To our knowledge, RESTART is the first randomised controlled trial to investigate the effects of starting versus avoiding

antiplatelet therapy in adults with previous intracerebral haemorrhage that occurred while taking antithrombotic (antiplatelet or anticoagulant) therapy, grouped by their brain imaging features. We did not find clinically or statistically significant hazardous effects of antiplatelet therapy on recurrent intracerebral haemorrhage or ischaemic stroke in primary subgroup analyses of cerebral microbleed presence, nor in any exploratory subgroup analyses of intracerebral haemorrhage location, previous vascular lesions, atrophy, periventricular lucencies, white matter hyperintensities, superficial siderosis, or diagnostic criteria for cerebral amyloid angiopathy.

### Implications of all the available evidence

Our results exclude all but a very modest harmful effect of antiplatelet therapy on the primary outcome of recurrent intracerebral haemorrhage in the presence of cerebral microbleeds. Our findings provide information about the safety of antiplatelet therapy in subgroups of adults with intracerebral haemorrhage, although the precision of these analyses was limited by small sample size. The directions of the effects we have found permit the inclusion of adults with a wide range of brain imaging features in ongoing trials (RESTART-Fr, NCT02966119; and STATICH, NCT03186729) and future randomised controlled trials of antiplatelet therapy after intracerebral haemorrhage, which are likely to require sample sizes of more than 2200 participants to detect statistically significant interactions with treatment effects.

up to six-times higher with presence versus absence of cerebral microbleeds on MRI,<sup>7</sup> and roughly four-times higher with presence versus absence of superficial siderosis on MRI.<sup>6</sup> Consequently, guidelines and opinions suggest that location of intracerebral haemorrhage and some features of cerebral small vessel diseases can guide therapeutic decisions.<sup>9–12</sup> However, decisions about antiplatelet therapy for patients with intracerebral haemorrhage and cerebral microbleeds are mainly informed by two analyses of a single-centre small observational cohort study of survivors of intracerebral haemorrhage,<sup>5,13</sup> one of which found an up to five-times greater risk of recurrent lobar intracerebral haemorrhage associated with use of aspirin in people with cerebral microbleeds.<sup>5</sup>

A randomised controlled trial is the most reliable test of overall treatment effects and enables estimation of heterogeneity in the effects of treatment in primary subgroup analyses (informed by previous evidence), as well as in other exploratory subgroup analyses.<sup>14</sup> One randomised trial found no heterogeneity by MRI features in the effects of aspirin and clopidogrel versus aspirin alone on stroke recurrence in 1278 adults after subcortical ischaemic stroke,<sup>15</sup> and two other trials found no heterogeneity by the presence of visible infarction on CT in the effects of aspirin versus control on stroke

recurrence in 31 072 adults after acute ischaemic stroke.<sup>16,17</sup> Randomised trials have not been done—but are needed—to investigate the effects of antiplatelet therapy after intracerebral haemorrhage according to brain imaging features of intracerebral haemorrhage or cerebral small vessel diseases.<sup>18</sup>

In the REstart or STop Antithrombotics Randomised Trial (RESTART), survivors of intracerebral haemorrhage that occurred while taking antithrombotic therapy who were randomly allocated to start antiplatelet therapy had fewer recurrences of symptomatic intracerebral haemorrhage over a median follow-up of 2·0 years than did those allocated to avoid antiplatelet therapy (12 [4%] of 268 vs 23 [9%] of 268, respectively; adjusted hazard ratio [HR] 0·51, 95% CI 0·25–1·03;  $p=0\cdot060$ ).<sup>19</sup> In a prespecified primary subgroup analysis, there was no evidence of heterogeneity of the effects of antiplatelet therapy on the primary outcome by investigators' categorisation of lobar versus non-lobar intracerebral haemorrhage location ( $p_{\text{interaction}}=0\cdot23$ ).<sup>19</sup> To further explore effects according to features of the intracerebral haemorrhage and cerebral small vessel diseases, we collected brain imaging performed on all participants before randomisation, and did primary subgroup analyses of cerebral microbleeds on MRI and exploratory subgroup analyses of other brain imaging features.

## Methods

### Study design and participants

RESTART was an investigator-led, pragmatic, multicentre, prospective, randomised, open-label, blinded-endpoint, parallel-group trial in 122 hospitals in the UK. Participant eligibility, consent, data collection, monitoring, approvals, procedures, and statistical analysis principles are described in detail in the protocol,<sup>20</sup> statistical analysis plan,<sup>21</sup> and primary report of the trial.<sup>19</sup>

Briefly, patients were eligible for enrolment if they were aged 18 years or older, had survived at least 24 h after spontaneous intracerebral haemorrhage, and were taking antithrombotic (antiplatelet or anticoagulant) therapy for the prevention of occlusive vascular disease at the onset of intracerebral haemorrhage, after which therapy was discontinued. Patients were ineligible if the intracerebral haemorrhage was attributable to preceding head injury, haemorrhagic transformation of an ischaemic stroke, or intracranial haemorrhage without intracerebral haemorrhage; or if they were still taking antithrombotic therapy at the time of consent (ie, after intracerebral haemorrhage). Patients, or a representative, provided written informed consent in inpatient or outpatient hospital settings. The Scotland A Research Ethics Committee approved the trial protocol.

Before randomisation, collaborators had to confirm that the brain imaging (usually CT, but sometimes MRI alone) that diagnosed the qualifying intracerebral haemorrhage was available and would be sent to the trial coordinating centre. Participants who had not already undergone brain MRI that complied with the trial's imaging protocol, and who were able and willing to undergo brain MRI, provided informed consent for this to be performed. Details of the randomisation method and masking are described in the protocol and primary report of the trial.<sup>19,20</sup>

### Procedures

The intervention of starting antiplatelet therapy was restricted to the use of one or more of oral aspirin, dipyridamole, or clopidogrel, begun within 24 h of randomisation. The comparator was a policy of avoiding antiplatelet therapy (ie, no placebo group).<sup>19,20</sup>

To be permitted to enrol participants in the MRI substudy, sites had to provide test imaging that passed image acquisition standards and adhered to the minimum requirements for sequences and parameters specified in the imaging protocol. Any field strength was permitted. Coverage from the very top of the vertex to the foramen magnum was essential. An axial gradient-recalled echo (GRE) T2\* sequence was required with specified slice thickness (3 mm optimal, 3–5 mm acceptable), slice gap (none optimal, not more than 1 mm acceptable), and echo time (20–30 ms optimal, 15–40 ms acceptable). The following MRI sequences were essential (although their sequence parameters were not specified): T1-weighted (volumetric preferred, otherwise sagittal), axial T2-weighted, axial diffusion-weighted imaging, and

fluid-attenuated inversion recovery (axial preferred). Brain MRI was only included if acquired from participants before randomisation to avoid the possibility that the allocated treatment might affect appearances.

Investigators copied the earliest imaging study that diagnosed the qualifying intracerebral haemorrhage and any brain MRI substudy images that were obtained before randomisation in Digital Imaging and Communications in Medicine (DICOM) format, removed personal identifiers and replaced these with a participant's study number (pseudo-anonymisation), and sent the images to the trial coordinating centre after randomisation.

The RESTART imaging manager checked each imaging study to ensure that the participant, timing, and modality corresponded to the information provided before randomisation. Each brain MRI study was checked to ensure that all the required sequences had been provided, using acceptable parameters. After quality assurance, all CT and MRI studies were uploaded to an electronic archive and allocated to one of a panel of consultant neuroradiologists via the in-house, web-based, systematic image review system for confirmation and characterisation of brain imaging features of intracerebral haemorrhage diagnosis and cerebral small vessel diseases.<sup>1,22</sup>

A member of the independent panel of consultant neuroradiologist adjudicators reviewed all imaging masked to treatment allocation before the trial database was locked and the randomisation code was broken.<sup>20</sup> The panel member checked eligibility of each participant by confirming that each imaging study demonstrated parenchymal haemorrhage, consistent with the given date of symptom onset, most likely due to intracerebral haemorrhage and not due to haemorrhagic transformation of ischaemic stroke. If the independent rating of the imaging studies did not confirm the existence of intracerebral haemorrhage, another member of the panel re-reviewed all relevant imaging studies and made a final determination of eligibility.

For CT imaging, the neuroradiologist used validated scales to rate features of the single (or largest, if multiple) intracerebral haemorrhage (side, location, volume in mL measured by the ABC/2 method,<sup>23</sup> intraventricular extension, subarachnoid extension, and subdural extension), the surrounding brain (previous vascular lesions<sup>22,24</sup> and periventricular lucencies [leukoaraiosis]<sup>25</sup>), and atrophy.<sup>22,26</sup> One neuroradiologist rated the features of acute intracerebral haemorrhages with a lobar epicentre (subarachnoid extension and finger-like projections) to estimate the probability of underlying cerebral amyloid angiopathy according to the CT-only version of the Edinburgh diagnostic criteria.<sup>2</sup>

For MRI, the neuroradiologist used validated scales to rate features of the single (or largest, if multiple) intracerebral haemorrhage (side, location, volume in mL measured by the ABC/2 method,<sup>23</sup> intraventricular extension, subarachnoid extension, and subdural extension), the surrounding brain (previous vascular lesions—ie,

For more on the systematic image review system tool see <https://sirs2.cchs.ed.ac.uk>

For the imaging protocol see [http://www.restarttrial.org/documents/RESTART\\_MRI\\_protocol.pdf](http://www.restarttrial.org/documents/RESTART_MRI_protocol.pdf)

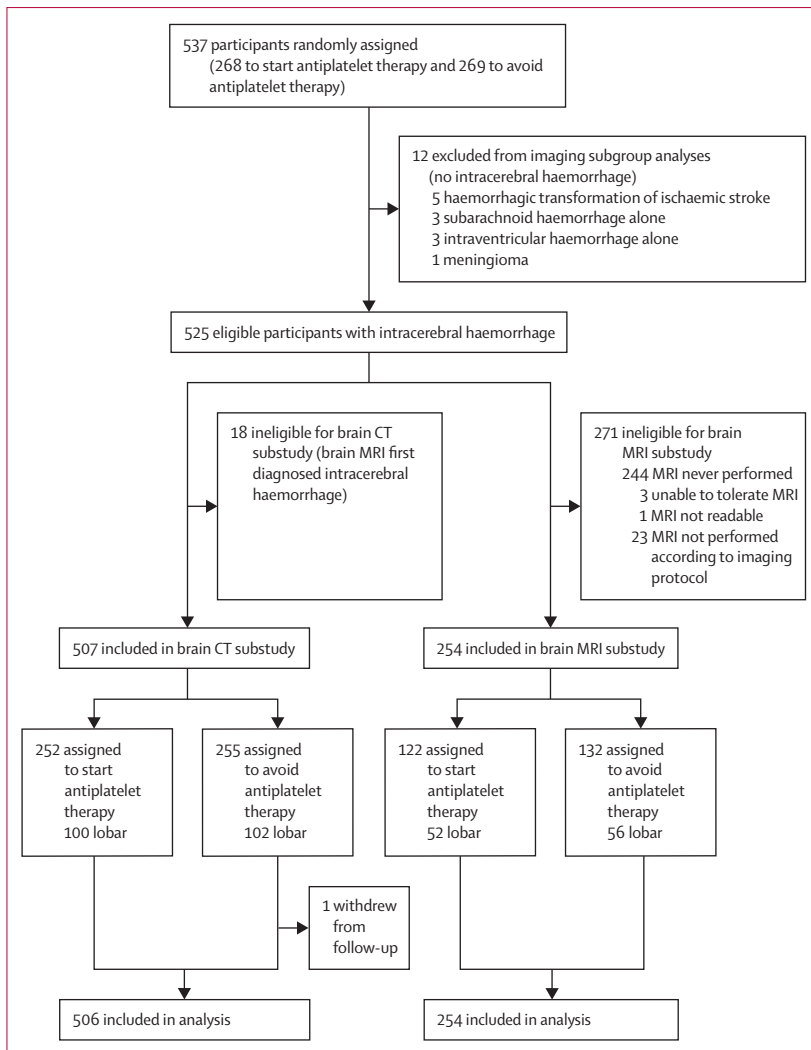


Figure 1: Profile of imaging substudies within RESTART

previous infarcts or previous haemorrhages that were not microbleeds),<sup>1,27</sup> superficial siderosis (focal or disseminated),<sup>3</sup> white matter hyperintensities of presumed vascular origin,<sup>28</sup> basal ganglia mineral deposits, enlarged perivascular spaces, atrophy,<sup>29</sup> and cerebral microbleed presence, number, and location,<sup>30,31</sup> as defined previously.<sup>1</sup>

### Outcomes

The RESTART trial's primary outcome (fatal or non-fatal radiographically or pathologically proven recurrent symptomatic intracerebral haemorrhage) and secondary outcomes have been reported elsewhere.<sup>19</sup> For this report, we analysed eligible participants with intracerebral haemorrhage according to their treatment allocation in primary subgroup analyses of presence, burden, and location of cerebral microbleeds on MRI and in exploratory subgroup analyses of other brain imaging features on CT or MRI. The secondary outcome

in the subgroup analyses of brain imaging features was ischaemic stroke. Outcomes were ascertained and adjudicated as described in the protocol and primary report of the trial.<sup>19,20</sup>

### Statistical analysis

In our protocol and statistical analysis plan,<sup>20,21</sup> we prespecified that the MRI substudy would focus on primary subgroup analyses, testing whether there was heterogeneity in the effects of antiplatelet therapy on the trial's primary outcome of recurrent intracerebral haemorrhage by the presence, number, or location of cerebral microbleeds. We collected other brain imaging features on MRI and CT for exploratory subgroup analyses of the effects of antiplatelet therapy on recurrent intracerebral haemorrhage or ischaemic stroke. We present the analyses of CT imaging features first because of their larger sample size, but focus our reporting on the primary subgroup analyses of cerebral microbleeds on brain MRI.

We intended to obtain diagnostic imaging studies for all participants and recruit approximately 75% of RESTART participants to the MRI substudy, although ultimately investigators recruited a smaller total number and proportion of all participants, diminishing the precision of our findings. In RESTART, brain imaging was not always done despite consent being obtained; was not always provided; was performed but might have contravened the required protocol; was performed, but might have been degraded by motion artefact; or was performed but demonstrated that the patient was ineligible for inclusion in RESTART (which precluded collection of ratings by the RESTART imaging panel). We quantified these exclusions, retaining participants in the imaging analyses if pre-randomisation brain imaging was obtained (and was compliant with the RESTART protocol in the case of MRI), was readable, and confirmed intracerebral haemorrhage. We recorded the timing of imaging (symptom onset to earliest imaging study and earliest imaging study to randomisation).

We focused descriptive analyses on imaging features of primary interest at a meeting between RA-SS, PMW, and JMW before database lock and unmasking the trial database. We chose not to analyse other features at this time (basal ganglia mineral deposits and enlarged perivascular spaces on MRI). We also agreed on pragmatic categorisations of some complex variables (eg, previous vascular lesions, periventricular lucencies, and atrophy) based on previous experience of simplifying the complex rating scales of these features for analysis.<sup>1,2,17,22,24,26,29</sup>

We prespecified that cerebral microbleed presence was two or more microbleeds (in view of inter-rater variation in the reporting of solitary microbleeds<sup>30,31</sup>) and that microbleed location would be grouped as strictly lobar versus other, for dichotomous analysis of the presence of cerebral microbleeds on MRI. We prespecified that for categorical analysis of cerebral microbleed number, the

split would be 0 or 1 versus 2–4 versus 5 or more.<sup>21</sup> We investigated whether cerebral microbleed presence and burden (as a continuous variable) were associated, as expected,<sup>7,32</sup> with the first recurrent intracerebral haemorrhage or ischaemic stroke in Cox proportional hazards regression models adjusted for the five covariates in the minimisation algorithm (qualifying intracerebral haemorrhage location, time since symptom onset, antiplatelet therapy preferred by the participant's physician if allocated to start, participant age at randomisation, and predicted probability of being alive and independent at 6 months). We analysed heterogeneity of the effects of antiplatelet therapy on the first recurrent intracerebral haemorrhage between subgroups using a statistical test of interaction, by including an interaction term between treatment group and each imaging feature in Cox proportional hazards regression models adjusted for the five covariates in the minimisation algorithm. We applied the Firth correction to Cox proportional hazards models in which we observed monotone likelihoods and calculated HRs with 95% profile likelihood confidence limits.<sup>33</sup> The unmasked trial statistician performed statistical analyses with SAS, version 9.4.

The trial is registered with the ISRCTN registry, number ISRCTN71907627.

### Role of the funding source

The funder of the study had no role in study design, data collection, data analysis, data interpretation, or writing of the report. The corresponding author had full access to all data in the study and had final responsibility for the decision to submit for publication.

### Results

Between May 22, 2013, and May 31, 2018, 537 participants were enrolled in the RESTART trial and randomly assigned to start antiplatelet therapy (n=268) or to avoid antiplatelet therapy (n=269), of whom 12 were ineligible for the imaging subgroup analyses because their intracranial haemorrhage did not extend into the brain parenchyma (figure 1). 18 participants were diagnosed using MRI alone, leaving 507 in the brain CT substudy. 271 participants did not undergo per-protocol MRI, leaving 254 in the brain MRI substudy.

In the brain CT substudy, the median time from symptom onset to earliest CT was 0 days (IQR 0–1) and the median time from earliest CT to randomisation was 74 days (27–144). The age and sex distributions of participants included in the CT substudy were similar to those of participants in the whole trial (table 1).<sup>19</sup> Most participants had a solitary intracerebral haemorrhage, 40% of which were lobar. After excluding eight participants whose first brain CT showed subacute intracerebral haemorrhage (which precluded accurate rating of brain imaging features of the haemorrhage<sup>2</sup>), 305 had non-lobar haemorrhage and the remaining 194 participants with CT of acute intracerebral haemorrhage with a lobar epicentre

	Start antiplatelet therapy (n=252)	Avoid antiplatelet therapy (n=255)
<b>Participant characteristics</b>		
Sex		
Female	89 (35%)	79 (31%)
Male	163 (65%)	176 (69%)
Age (years)	77 (69–83)	76 (70–82)
Number of intracerebral haemorrhages		
One	235 (93%)	242 (95%)
More than one	17 (7%)	13 (5%)
<b>Characteristics of the largest intracerebral haemorrhage</b>		
Side		
Left	120 (48%)	117 (46%)
Right	132 (52%)	138 (54%)
Location		
Deep	123 (49%)	123 (48%)
Infratentorial	29 (12%)	30 (12%)
Lobar	100 (40%)	102 (40%)
Volume of largest intracerebral haemorrhage (mL)	3.7 (1.1–10.8)	4.3 (1.2–11.6)
Intraventricular extension	55 (22%)	70 (27%)
Subarachnoid extension	42 (17%)	50 (20%)
Subdural extension	6 (2%)	8 (3%)
Edinburgh CT-only criteria <sup>2</sup> for acute intracerebral haemorrhages with lobar epicentres (n=499)*		
Non-lobar intracerebral haemorrhage	152 (61%)	153 (61%)
Lower probability of cerebral amyloid angiopathy	83 (33%)	82 (33%)
High probability of cerebral amyloid angiopathy	14 (6%)	15 (6%)
<b>Characteristics of the brain</b>		
Previous vascular lesions		
No	98 (39%)	93 (36%)
Yes	154 (61%)	162 (64%)
Periventricular lucencies score†		
0–2	165 (65%)	147 (58%)
3–4	87 (35%)	108 (42%)
Atrophy score‡		
0–2	215 (85%)	212 (83%)
3–4	37 (15%)	43 (17%)
Data are n (%) or median (IQR). *Eight participants whose first brain CT showed subacute intracerebral haemorrhage (which precluded accurate rating of brain imaging features of the haemorrhage) were excluded. Start antiplatelet therapy, n=249; avoid antiplatelet therapy, n=250. High probability of cerebral amyloid angiopathy is defined as finger-like projections and subarachnoid extension; lower probability is all other features. †Periventricular lucencies score combines both anterior and posterior white matter scores (0=no lucency; 1=lucency restricted to region adjoining ventricles; 2=lucency covering entire region from lateral ventricle to cortex). ‡Atrophy score combines both central and cortical atrophy (each scored 0=none; 1=moderate; 2=severe).		
<b>Table 1: Baseline characteristics of participants in the CT substudy</b>		

were rated for the probability of underlying cerebral amyloid angiopathy according to the Edinburgh diagnostic criteria:<sup>2</sup> 29 (6%) of 499 participants had a high probability (finger-like projections and subarachnoid extension) and 165 (33%) had a lower probability. Participants' brains



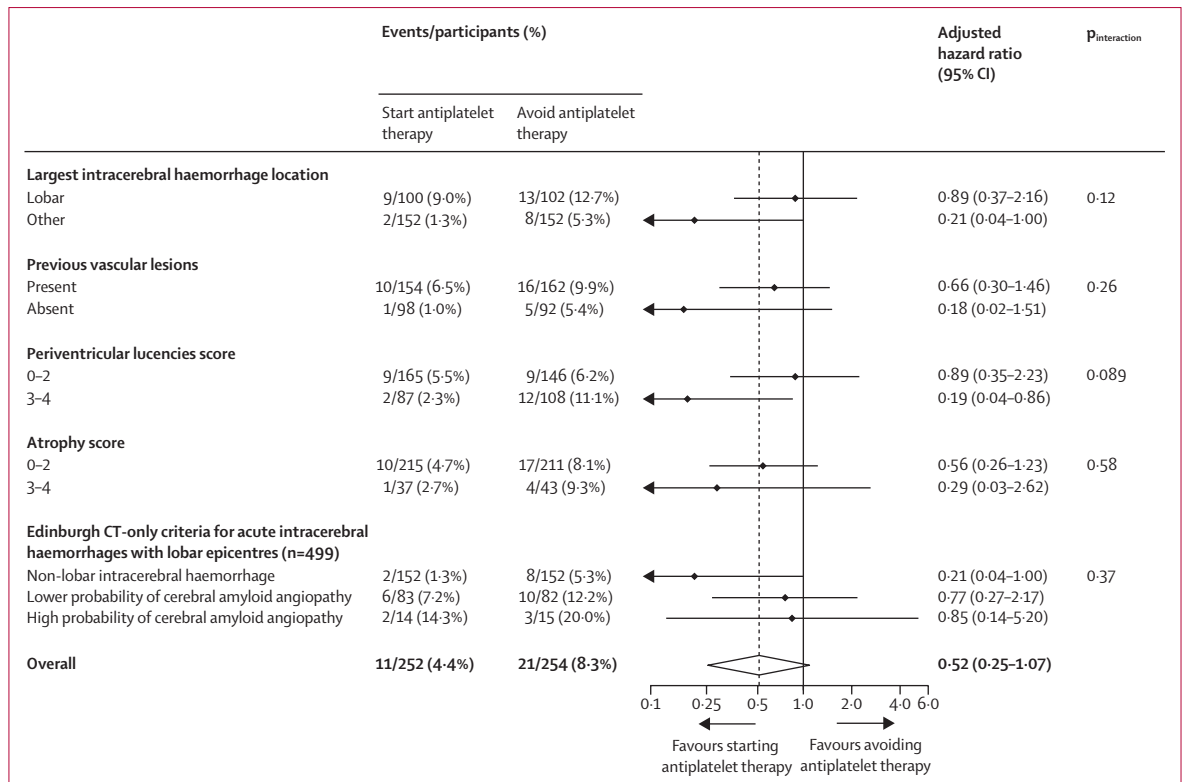


Figure 2: Prespecified exploratory subgroup analyses of the risk of first recurrent symptomatic intracerebral haemorrhage (the primary outcome) by brain CT features

commonly showed previous vascular lesions (316 [62%] of 507), severe periventricular lucencies (195 [38%]), and moderate-to-severe atrophy (80 [16%]). There were small baseline imbalances in intraventricular extension, subarachnoid extension, and periventricular lucencies (table 1). One participant in the avoid antiplatelet therapy group of the brain CT substudy withdrew from follow-up and was not included in the analyses.

In prespecified exploratory subgroup analyses of CT features, we did not find strong evidence of statistically significant heterogeneity in the effects of antiplatelet therapy on recurrent intracerebral haemorrhage (figure 2) or ischaemic stroke (appendix) by intracerebral haemorrhage location, previous vascular lesions, periventricular lucencies, atrophy, or the probability of underlying cerebral amyloid angiopathy.

In the brain MRI substudy, the median time from symptom onset to MRI was 55 days (IQR 18–102) and the median time from MRI to randomisation was 2 days (0–18). The age and sex distributions of participants included in the MRI substudy were similar to those of participants in the whole trial (table 2).<sup>19</sup> 108 (43%) of 254 substudy participants had lobar intracerebral haemorrhage and 235 (93%) had a GRE T2\* MRI sequence of sufficient quality to rate cerebral microbleeds: 93 (40%) of 235 had two or more microbleeds, 62 (26%) of 235 had five or more microbleeds, and 20 (22%) of 93 had strictly

lobar microbleeds, such that 47 (20%) of 235 probably had cerebral amyloid angiopathy and 30 (13%) of 235 possibly had cerebral amyloid angiopathy according to the modified Boston criteria.<sup>3</sup> Background brain characteristics on MRI (table 2) were very similar to characteristics on CT (table 1). There were small baseline imbalances in sex, intracerebral haemorrhage location and extension, atrophy, and cerebral microbleed strictly lobar location (table 2).

As was expected in this population,<sup>7,32</sup> in the primary subgroup of 235 participants with cerebral microbleeds, their presence (2 or more versus 0 or 1) and burden (linear trend of 0 or 1, 2–4, and 5 or more) were associated with first recurrent intracerebral haemorrhage (adjusted HR 3.62 [95% CI 1.34–9.79] and 1.99 [1.20–3.31], respectively) and ischaemic stroke (HR 1.92 [0.83–4.46] and 1.62 [1.03–2.55], respectively; appendix).

We did not find clinically or statistically significant hazardous effects of antiplatelet therapy on recurrent intracerebral haemorrhage in any primary subgroup analyses of cerebral microbleed presence versus absence (HR 0.30 [95% CI 0.08–1.13] vs 0.77 [0.13–4.61];  $P_{interaction}=0.41$ ), cerebral microbleed number 0–1 versus 2–4 versus 5 or more (HR 0.77 [0.13–4.62] vs 0.32 [0.03–3.66] vs 0.33 [0.07–1.60]);  $P_{interaction}=0.75$ ), or strictly lobar versus other location (HR 0.52 [0.004–6.79] vs 0.37 [0.09–1.28];  $P_{interaction}=0.85$ ; figure 3).

	Start antiplatelet therapy (n=122)	Avoid antiplatelet therapy (n=132)
<b>Participant characteristics</b>		
Sex		
Female	42 (34%)	36 (27%)
Male	80 (66%)	96 (73%)
Age (years)	76 (70–81)	75 (69–82)
Number of intracerebral haemorrhages		
One	117 (96%)	124 (94%)
More than one	5 (4%)	8 (6%)
<b>Characteristics of the largest intracerebral haemorrhage</b>		
Side		
Left	56 (46%)	59 (45%)
Right	66 (54%)	73 (55%)
Location		
Deep	53 (43%)	66 (50%)
Infratentorial	17 (14%)	10 (8%)
Lobar	52 (43%)	56 (42%)
Volume of largest intracerebral haemorrhage (mL)	2.3 (0.4–7.9)	1.6 (0.4–7.1)
Intraventricular extension	10 (8%)	13 (10%)
Subarachnoid extension	17 (14%)	26 (20%)
Subdural extension	2 (2%)	8 (6%)

(Table 2 continues in next column)

In prespecified exploratory subgroup analyses of other MRI features, we did not find strong evidence of statistically significant heterogeneity in the effects of antiplatelet therapy on recurrent intracerebral haemorrhage (figure 3) or ischaemic stroke (appendix; all  $p_{\text{interaction}} > 0.05$ ).

## Discussion

In these subgroup analyses of the RESTART trial, the estimated effect of antiplatelet therapy in the subgroup with cerebral microbleeds (HR 0.30, 95% CI 0.08–1.13) excluded all but a very modest harmful effect of antiplatelet therapy on the primary outcome of recurrent intracerebral haemorrhage. Moreover, we did not find strong evidence of any significant heterogeneity of the effects of antiplatelet therapy on recurrent intracerebral haemorrhage or ischaemic stroke in exploratory subgroup analyses of other CT or MRI features of the intracerebral haemorrhage or cerebral small vessel diseases.

Although caution is needed in the interpretation of non-significant differences between small subgroups,<sup>14</sup> we did not find strong evidence within the primary subgroup analyses of cerebral microbleeds that was consistent with the five-times greater risk of recurrent lobar intracerebral haemorrhage associated with aspirin use in people with cerebral microbleeds as seen in an observational study,<sup>5</sup> which has hitherto influenced clinical practice.<sup>9,34</sup> Furthermore, we did not find strong evidence of differences within exploratory subgroup analyses to suggest that superficial siderosis or diagnostic criteria for cerebral amyloid angiopathy might modify the risk of intracerebral

	Start antiplatelet therapy (n=122)	Avoid antiplatelet therapy (n=132)
(Continued from previous column)		
<b>Characteristics of the brain</b>		
Previous ischaemic lesions		
None	72 (59%)	74 (56%)
One	18 (15%)	25 (19%)
More than one	32 (26%)	33 (25%)
Previous haemorrhagic lesions (that are not cerebral microbleeds)		
None	110 (90%)	112 (85%)
One	12 (10%)	18 (14%)
More than one	0	2 (2%)
Superficial siderosis		
None	95 (78%)	99 (75%)
Focal	19 (16%)	23 (17%)
Disseminated	8 (7%)	10 (8%)
White matter hyperintensities score*		
0–2	39 (32%)	43 (33%)
3–6	83 (68%)	89 (67%)
Atrophy score†		
0–2	76 (62%)	71 (54%)
3–4	46 (38%)	61 (46%)
Cerebral microbleeds (n=235)‡		
Presence		
0–1	66 (58%)	76 (63%)
2–4	16 (14%)	15 (12%)
5 or more	32 (28%)	30 (25%)
Location§		
Strictly lobar	7 (15%)	13 (29%)
Other	41 (85%)	32 (71%)
Modified Boston criteria <sup>3</sup> for participants with ratings for microbleeds and superficial siderosis		
Probable cerebral amyloid angiopathy	19 (17%)	28 (23%)
Possible cerebral amyloid angiopathy	14 (12%)	16 (13%)
Neither probable nor possible cerebral amyloid angiopathy	81 (71%)	77 (64%)

Data are n (%) or median (IQR). \*White matter hyperintensities score combines periventricular and deep (subcortical) white matter (each scored as 0, 1, 2, or 3). †Atrophy score combines central and cortical (each scored 0=none; 1=moderate; 2=severe). ‡235 participants had an MRI sequence of sufficient quality to rate cerebral microbleeds; start antiplatelet therapy, n=114; avoid antiplatelet therapy, n=121. §Denominators are start antiplatelet therapy, n=48; avoid antiplatelet therapy, n=45.

**Table 2: Baseline characteristics of participants in the MRI substudy**

haemorrhage with antiplatelet therapy.<sup>5,35</sup> Although these brain imaging features are associated with higher absolute risks of intracerebral haemorrhage recurrence in observational studies,<sup>6,7</sup> we did not find strong evidence that there was heterogeneity in the effects of antiplatelet therapy in these subgroups.

To our knowledge, RESTART is the first randomised trial comparing starting versus avoiding antiplatelet therapy after intracerebral haemorrhage to explore whether the

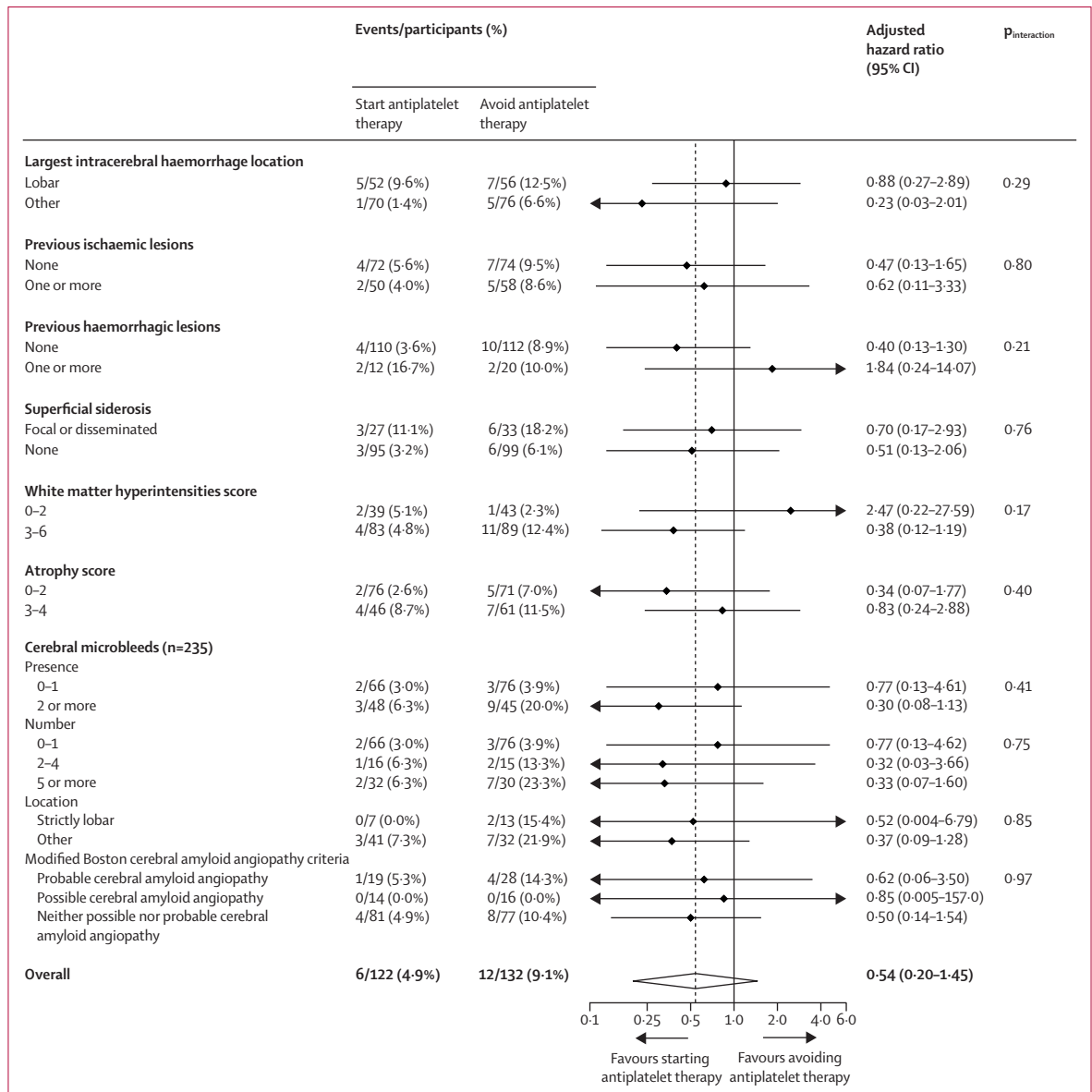


Figure 3: Prespecified primary and exploratory subgroup analyses of the risk of first recurrent symptomatic intracerebral haemorrhage (the primary outcome) by brain MRI features

effects of antiplatelet therapy vary by imaging features of intracerebral haemorrhage or cerebral small vessel diseases. The main strengths of the trial are described elsewhere.<sup>19</sup> The additional strengths of the imaging sub-studies are that they relied on imaging acquired before randomisation (so appearances could not have been affected by allocated treatment), imaging was performed in everyday clinical practice, MRI was done according to a standardised protocol, imaging was collected centrally in DICOM format, and adjudicated by experienced neuro-radiologists masked to treatment allocation and outcome using validated rating scales.

The overall characteristics of participants in the trial were similar to those of patients in observational hospital-based

studies of antiplatelet therapy use after intracerebral haemorrhage in clinical practice.<sup>5,19</sup> However, the external validity of our findings can be judged by participants' imaging characteristics, which reflect the inclusion of survivors with haemorrhages that were smaller and had a lower prevalence of subarachnoid and intraventricular extension than those in all-inclusive population-based studies.<sup>2,36</sup> Therefore, our findings are generalisable to adults who survived a median of 76 days after intracerebral haemorrhage, most of whom had good functional ability and few of whom had a low probability of good functional outcome at 6 months,<sup>19</sup> in part because of the volumes of their intracerebral haemorrhages, which were smaller than those in population-based studies.<sup>2,36</sup>



The sample size resulted in some small baseline imbalances. The numbers of outcomes were not large enough to detect small or modest differences between subgroups, in particular those brain imaging features that have been proposed to modify the effects of antiplatelet therapy, such as cerebral microbleeds and superficial siderosis.<sup>5,10,13</sup> However, the extent of heterogeneity in the effects of antiplatelet therapy after intracerebral haemorrhage by brain imaging features was unknown before the trial started, so we could not accurately estimate the sample sizes required to adequately power our subgroup analyses.

In clinical practice, physicians and patients might be reassured by our finding that excluded all but a very modest harmful effect of antiplatelet therapy on recurrent intracerebral haemorrhage in the presence of brain microbleeds. This finding might encourage changes to the current risk-averse approach of not using antiplatelet therapy after intracerebral haemorrhage, driven by findings from a small observational study.<sup>5,9,10,34</sup> Moreover, there was no strong evidence of heterogeneity between subgroups, and the effect estimates in almost all subgroups were consistent with the trial's overall finding that antiplatelet therapy might reduce the risk of recurrent intracerebral haemorrhage. Furthermore, despite the association between superficial siderosis and recurrent intracerebral haemorrhage,<sup>6</sup> the effect of antiplatelet therapy on recurrent intracerebral haemorrhage in people with superficial siderosis (HR 0.70, 95% CI 0.17–2.93) might affect clinical equipoise and increase recruitment of people with this imaging feature in future randomised trials of antithrombotic therapies.

The directions and magnitudes of the effects we have found should help to inform the precision of subgroup analyses in imaging substudies in ongoing trials (RESTART-Fr, NCT02966119; and STATICH, NCT03186729) and future randomised controlled trials of antithrombotic therapy after intracerebral haemorrhage. These randomised trials are needed to investigate our findings with greater precision. It is a frequent misconception that risk factors for stroke recurrence in observational studies, such as cerebral microbleeds,<sup>7,32</sup> are also modifiers of the effects of antithrombotic therapies, although this can only be investigated in randomised controlled trials with larger sample sizes.

Our findings provide the opportunity to estimate the minimum sample size that would be required to demonstrate a potentially statistically significant subgroup interaction with the effects of antiplatelet therapy in this population. If we assume that having more periventricular lucencies causes a four-times greater risk of recurrent intracerebral haemorrhage (HR 0.19 [95% CI 0.04–0.86] for 0–2 periventricular lucencies vs 0.89 [0.35–2.23] for 3–4;  $p_{\text{interaction}}=0.089$ ), then to detect such an interaction in a future parallel-group randomised trial, assuming similar event rates over 2 years of follow-up, with 90% power at the 5% significance level, a sample size of

at least 2200 participants would be needed (or at least 3000 participants at the 1% significance level).

In summary, we excluded all but a very modest harmful effect of antiplatelet therapy on recurrent intracerebral haemorrhage in the presence of brain microbleeds and we did not find strong evidence of heterogeneity in the effects of antiplatelet therapy by other brain imaging features. Further randomised trials are needed to replicate these findings and investigate them with greater precision.

#### Contributors

RA-SS (chief investigator), MSD, GDM, DEN, PAGS, CLMS, PMW, WNW, and DJW obtained funding and developed the protocol. RA-SS, PMW, and JMW conceived the imaging substudies of RESTART, and designed and managed the imaging data collection and rating. PMW, DPM, DM, MAR, PB, JCdP, and YJ performed imaging assessments. JMW provided information on imaging assessment methods, contributed to the design of the imaging assessment, supported the imaging data collection and infrastructure that enabled the blinded image rating, advised on image acquisition, collection, management, assessment, rating, and analysis, and data interpretation. GDM was the masked trial statistician. JS was the unmasked trial statistician who did the data analyses. RA-SS and PMW drafted the report. All authors commented on drafts and approved the final version. PMW, RA-SS, JS, and JMW had full access to all the data.

#### Declaration of interests

RA-SS and GDM report a grant from the British Heart Foundation (SP/12/2/29422) paid to the University of Edinburgh for the conduct of RESTART. RA-SS reports grants from the Stroke Association, Chest Heart and Stroke Scotland, and GE Healthcare, outside the submitted work. DEN reports grants and personal fees from AstraZeneca, Eli Lilly, Bristol-Myers Squibb, and Janssen during the conduct of the study. PAGS reports funding from Bayer, outside the submitted work. NS reports a grant from the National Institute for Health Research Health Technology Assessment for the TICH-2 trial, outside the submitted work. DJW reports personal fees from Bayer and JFB Consulting, outside the submitted work. WNW reports a Chief Scientist Office of the Scottish Government Health Department Senior Fellowship (SCAF\_17\_01) and a grant from the European Stroke Organisation, outside the submitted work. JMW reports grants from EU Framework 7, the Medical Research Council, the British Heart Foundation, and the Wellcome Trust, outside the submitted work. PMW reports personal fees from Stryker Global Advisory Board on Haemorrhagic Stroke and MicroVention-Terumo, and a grant from MicroVention-Terumo, outside the submitted work. All other authors declare no competing interests.

#### Data sharing

A fully anonymised version of the dataset used for analysis with individual participant data and a data dictionary will be available for other researchers to apply to use 1 year after publication, via <https://datashare.is.ed.ac.uk/handle/10283/3265>. Written proposals will be assessed by members of the RESTART trial steering committee and a decision made about the appropriateness of the use of data. A data sharing agreement will be put in place before any data are shared.

#### Acknowledgments

We thank all participants, their relatives or carers, and their primary care practitioners; RESTART sites that recruited participants; the outcome event adjudicators; and the trial steering committee and the data monitoring committee. We are grateful to the independent members of the trial steering committee: Colin Baigent (MRC Population Health Research Unit, University of Oxford, Oxford, UK), Daniel S Lasserion (Institute of Applied Health Research, University of Birmingham, Birmingham, UK), and Johanna Carrie. We thank Edinburgh Clinical Trials Unit and the University of Edinburgh's Systematic Management, Archiving and Reviewing of Trial Images Service for their involvement. We thank the British Heart Foundation for funding the trial with a Special Project Grant (SP/12/2/20422) and continuing to support it while recruitment was challenging. The University of Edinburgh and the

Lothian Health Board are co-sponsors. We acknowledge the support of the National Institute for Health Research Clinical Research Network, National Health Service Research Scotland (NRS) Scottish Stroke Research Network, and the support of the NRS through the Edinburgh Clinical Research Facility (E131252) and NHS Lothian Research and Development. Imaging acquisition, processing, and data collection were performed at the Edinburgh Imaging Facility, University of Edinburgh, which is part of the SINAPSE collaboration funded by the Scottish Funding Council and the Chief Scientist Office.

#### References

- 1 Wardlaw JM, Smith EE, Biessels GJ, et al. Neuroimaging standards for research into small vessel disease and its contribution to ageing and neurodegeneration. *Lancet Neurol* 2013; **12**: 822–38.
- 2 Rodrigues MA, Samarasekera N, Lerpiniere C, et al. The Edinburgh CT and genetic diagnostic criteria for lobar intracerebral haemorrhage associated with cerebral amyloid angiopathy: model development and diagnostic test accuracy study. *Lancet Neurol* 2018; **17**: 232–40.
- 3 Linn J, Halpin A, Demaerel P, et al. Prevalence of superficial siderosis in patients with cerebral amyloid angiopathy. *Neurology* 2010; **74**: 1346–50.
- 4 Qiu J, Ye H, Wang J, Yan J, Wang J, Wang Y. Antiplatelet therapy, cerebral microbleeds, and intracerebral hemorrhage: a meta-analysis. *Stroke* 2018; **49**: 1751–54.
- 5 Biffi A, Halpin A, Towfighi A, et al. Aspirin and recurrent intracerebral hemorrhage in cerebral amyloid angiopathy. *Neurology* 2010; **75**: 693–98.
- 6 Charidimou A, Boulouis G, Roongpiboonsopit D, et al. Cortical superficial siderosis and recurrent intracerebral hemorrhage risk in cerebral amyloid angiopathy: large prospective cohort and preliminary meta-analysis. *Int J Stroke* 2019; published online Feb 20. DOI:10.1177/1747493019830065.
- 7 Charidimou A, Imaizumi T, Moulin S, et al. Brain hemorrhage recurrence, small vessel disease type, and cerebral microbleeds: a meta-analysis. *Neurology* 2017; **89**: 820–29.
- 8 Poon MT, Fonville AF, Al-Shahi Salman R. Long-term prognosis after intracerebral haemorrhage: systematic review and meta-analysis. *J Neurol Neurosurg Psychiatry* 2014; **85**: 660–67.
- 9 Hemphill JC 3rd, Greenberg SM, Anderson CS, et al. Guidelines for the management of spontaneous intracerebral hemorrhage: a guideline for healthcare professionals from the American Heart Association/American Stroke Association. *Stroke* 2015; **46**: 2032–60.
- 10 Wilson D, Werring DJ. Antithrombotic therapy in patients with cerebral microbleeds. *Curr Opin Neurol* 2017; **30**: 38–47.
- 11 Wang Z, Soo YO, Mok VC. Cerebral microbleeds: is antithrombotic therapy safe to administer? *Stroke* 2014; **45**: 2811–17.
- 12 Haley KE, Greenberg SM, Gurol ME. Cerebral microbleeds and macrobleeds: should they influence our recommendations for antithrombotic therapies? *Curr Cardiol Rep* 2013; **15**: 425.
- 13 Viswanathan A, Rakich SM, Engel C, et al. Antiplatelet use after intracerebral hemorrhage. *Neurology* 2006; **66**: 206–09.
- 14 Kent DM, Rothwell PM, Ioannidis JP, Altman DG, Hayward RA. Assessing and reporting heterogeneity in treatment effects in clinical trials: a proposal. *Trials* 2010; **11**: 85.
- 15 Shoamanesh A, Pearce LA, Bazan C, et al. Microbleeds in the Secondary Prevention of Small Subcortical Strokes Trial: stroke, mortality, and treatment interactions. *Ann Neurol* 2017; **82**: 196–207.
- 16 Chen ZM, Sandercock P, Pan HC, et al. Indications for early aspirin use in acute ischemic stroke: a combined analysis of 40 000 randomized patients from the chinese acute stroke trial and the international stroke trial. *Stroke* 2000; **31**: 1240–49.
- 17 Wardlaw JM, West TM, Sandercock PA, Lewis SC, Mielke O, International Stroke Trials Collaborative Group. Visible infarction on computed tomography is an independent predictor of poor functional outcome after stroke, and not of haemorrhagic transformation. *J Neurol Neurosurg Psychiatry* 2003; **74**: 452–58.
- 18 Perry LA, Berge E, Bowditch J, et al. Antithrombotic treatment after stroke due to intracerebral haemorrhage. *Cochrane Database Syst Rev* 2017; **5**: CD012144.
- 19 RESTART Collaboration. Effects of antiplatelet therapy after stroke due to intracerebral haemorrhage (RESTART): a randomised, open-label trial. *Lancet* 2019; published online May 22. [http://dx.doi.org/10.1016/S0140-6736\(19\)30840-2](http://dx.doi.org/10.1016/S0140-6736(19)30840-2).
- 20 Al-Shahi Salman R, Dennis MS, Murray GD, et al. The REstart or STop Antithrombotics Randomised Trial (RESTART) after stroke due to intracerebral haemorrhage: study protocol for a randomised controlled trial. *Trials* 2018; **19**: 162.
- 21 Al-Shahi Salman R, Murray GD, Dennis MS, et al. The Restart or Stop Antithrombotics Randomised Trial (RESTART) after stroke due to intracerebral haemorrhage: statistical analysis plan for a randomised controlled trial. *Trials* 2019; **20**: 183.
- 22 IST-3 Collaborative Group. Association between brain imaging signs, early and late outcomes, and response to intravenous alteplase after acute ischaemic stroke in the third International Stroke Trial (IST-3): secondary analysis of a randomised controlled trial. *Lancet Neurol* 2015; **14**: 485–96.
- 23 Newman GC. Clarification of ABC/2 rule for ICH volume. *Stroke* 2007; **38**: 862.
- 24 Wardlaw JM, Sellar R. A simple practical classification of cerebral infarcts on CT and its interobserver reliability. *AJNR Am J Neuroradiol* 1994; **15**: 1933–39.
- 25 van Swieten JC, Hijdra A, Koudstaal PJ, van Gijn J. Grading white matter lesions on CT and MRI: a simple scale. *J Neurol Neurosurg Psychiatry* 1990; **53**: 1080–83.
- 26 Wardlaw JM, Farrall AJ, Perry D, et al. Factors influencing the detection of early CT signs of cerebral ischemia: an internet-based, international multiobserver study. *Stroke* 2007; **38**: 1250–56.
- 27 Smith EE, Rosand J, Greenberg SM. Imaging of hemorrhagic stroke. *Magn Reson Imaging Clin N Am* 2006; **14**: 127–40, v.
- 28 Fazekas F, Chawluk JB, Alavi A, Hurtig HI, Zimmerman RA. MR signal abnormalities at 1.5 T in Alzheimer's dementia and normal aging. *AJR Am J Roentgenol* 1987; **149**: 351–56.
- 29 Farrell C, Chappell F, Armitage PA, et al. Development and initial testing of normal reference MR images for the brain at ages 65–70 and 75–80 years. *Eur Radiol* 2009; **19**: 177–83.
- 30 Cordonnier C, Potter GM, Jackson CA, et al. Improving interrater agreement about brain microbleeds: development of the Brain Observer MicroBleed Scale (BOMBS). *Stroke* 2009; **40**: 94–99.
- 31 Gregoire SM, Chaudhary UJ, Brown MM, et al. The Microbleed Anatomical Rating Scale (MARS): reliability of a tool to map brain microbleeds. *Neurology* 2009; **73**: 1759–66.
- 32 Wilson D, Charidimou A, Ambler G, et al. Recurrent stroke risk and cerebral microbleed burden in ischemic stroke and TIA: a meta-analysis. *Neurology* 2016; **87**: 1501–10.
- 33 Heinze G, Schemper M. A solution to the problem of monotone likelihood in Cox regression. *Biometrics* 2001; **57**: 114–19.
- 34 Falcone GJ, Rosand J. Aspirin should be discontinued after lobar intracerebral hemorrhage. *Stroke* 2014; **45**: 3151–52.
- 35 Charidimou A, Linn J, Vernooij MW, et al. Cortical superficial siderosis: detection and clinical significance in cerebral amyloid angiopathy and related conditions. *Brain* 2015; **138**: 2126–39.
- 36 Samarasekera N, Fonville A, Lerpiniere C, et al. Influence of intracerebral hemorrhage location on incidence, characteristics, and outcome: population-based study. *Stroke* 2015; **46**: 361–68.